Artefacts from Blood Smears*

MARSHALL LAIRD, M.Sc., Ph.D., Department of Zoology,

Issued 1st December, 1951

ABSTRACT

Organisms recorded in this account as contaminants of blood smears include flagellates of the genera *Monocercomonoides* and *Chilomastix*, bacteria resembling *Eperythrozoon*, and a vegetable cell resembling a *Sarcocystis* spore. Attention is drawn to errors which could result from describing material found in blood smears prepared by field assistants, without full knowledge of the manner and circumstances of collection.

The material discussed in this account was obtained during a study of the blood parasites of animals of New Zealand, extending over the period 1947–49.

I have pleasure in acknowledging the assistance of Mr. R. I. Kean, who made the preparations from wallabies, and of Mr. W. H. I. Dawbin, who made those from whales.

Eperythrozoon-LIKE BODIES (Text-figure 1).

Blood smears were taken from 50 Australian black-tailed wallabies, *Wallabia ualabatus* (Lesson and Garnier), shot at Waimate in July, 1947. Those from seven animals proved to contain numerous bodies resembling *Eperythrozoon* Schilling. The bodies are in the form of rings occurring either free in the plasma (Text-fig. 1,

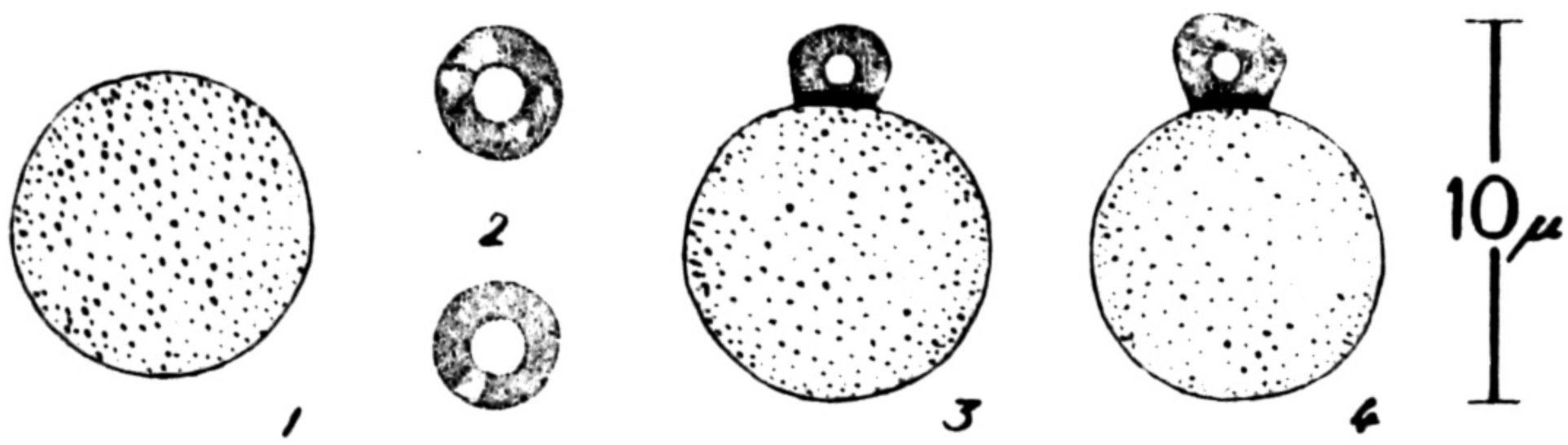

TEXT-FIGURE 1

1—Erythrocyte of *Wallabia ualabatus*.
2—Free *Eperythrozoon*-like bodies.
3 and 4—Epierythrocytic *Eperythrozoon*-like bodies.

Fig. 2) or attached to the outer surface of erythrocytes (Text-fig. 1, Figs. 3 and 4). They stain reddish-purple with Giemsa, the free forms often having lighter staining maculations (Text-fig. 1, Fig. 2). Epierythrocytic forms stain more intensely on the side in contact with the red cell, as Tyzzer (1942) states to be the case for *Eperythrozoon varians*. The greatest diameter of these bodies ranges from 1.0μ to 3.3μ. Weinman (1944) claims that members of the genus *Eperythrozoon* do not exceed 2.0μ in diameter. The rings of *Eperythrozoon* are characteristically delicate structures, Dinger (quoted by Weinman) estimating the non-staining central zone of *E. coccoides* to occupy 80 per cent. of the total area of the organism. In the more massive ring bodies from *Wallabia ualabatus*, the central clear zone occupies only 6 per cent. to 15 per cent. of the total area.

**These observations were made in the course of studies undertaken with the aid of a New Zealand University Research Fund Fellowship.*

All seven infected preparations are heavily contaminated with various bacteria. At first sight some of these could easily be confused with the solid discs and rods which accompany the rings of *Eperythrozoon*, but the manner of their occurrence in clumps, often associated with partly-laked areas of the smears, adjacent areas being clean and free from bacteria, points to external contamination. All the wallaby smears were prepared by an investigator working under trying field conditions, and I was subsequently informed that many of them had been made directly from shot wounds. Wenyon (1926) emphasizes that films made under such conditions almost always become contaminated with bacteria from the skin or wounded intestine. No *Eperythrozoon*-like bodies were found in any of the uncontaminated smears forwarded. These bodies are thus regarded as bacterial artefacts which entered the blood from some external source during the preparation of the smears concerned. Numbers of the bodies, having become attached to the outer surfaces of the erythrocytes, bear a superficial resemblance to epierythrocytic forms of *Eperythrozoon*. They may be distinguished from organisms of this genus by their appreciably greater size and the much smaller area of the central clear zone in relation to the total area of the body.

BACTERIA AND A SPIROCHAETE (Text-figure 2).

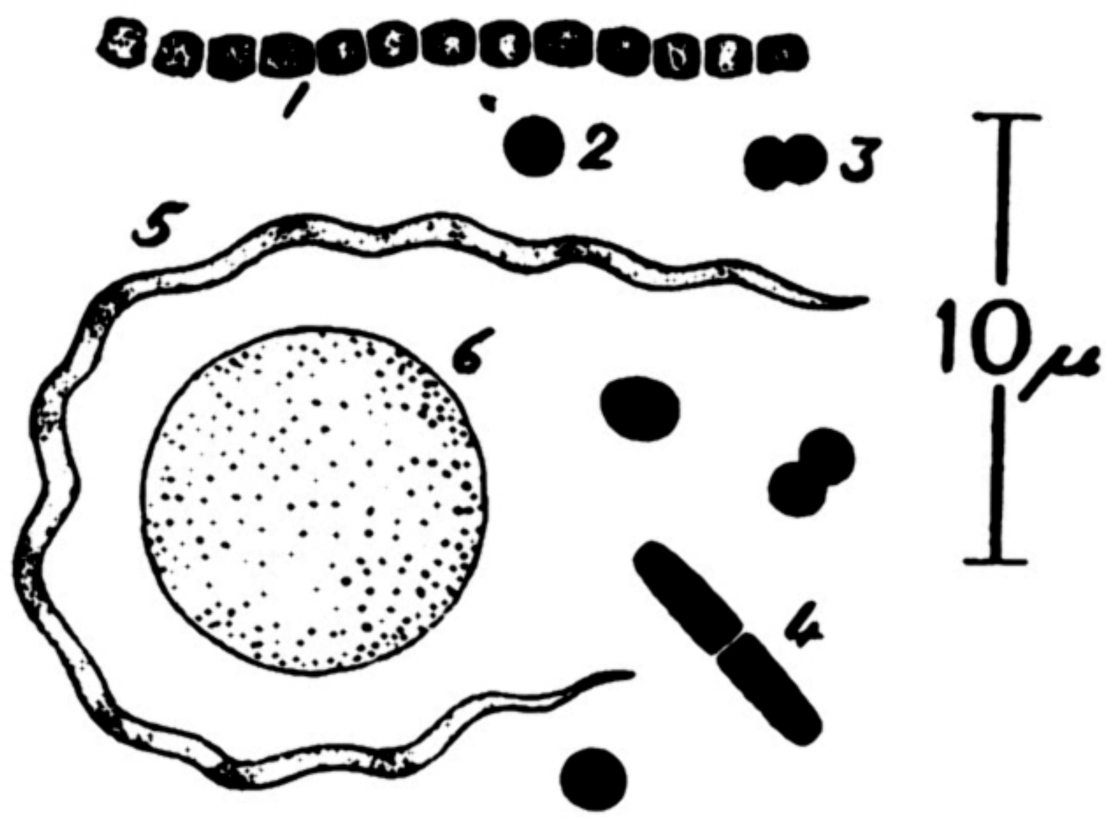

TEXT-FIGURE 2
Bacteria (1–4) and a spirochaete (5) from whale blood. 6—Erythrocyte of *Megaptera nodosa*.

Smears of the peripheral blood of three of four specimens of the humpback whale, *Megaptera nodosa* (Bonaterre), obtained at Tory Channel whaling station during June, 1948, were found to contain great numbers of bacteria. Streptococci (Text-fig. 2, Fig. 1), cocci (Text-fig. 2, Figs. 2, 3, etc.), and bacilli (Text-fig. 2, Fig. 4), also a single spirochaete (Text-fig. 2, Fig. 5), were encountered.

All the bacteria stain a dense blue with Giemsa. The cocci range in diameter from 0.8μ to 1.7μ, and closely resemble the bodies described by Laurie (1933) as X organisms. Laurie found his organisms in all samples of blood which he took from adult and foetal blue and fin whales, describing them as having an indefinite but approximately spherical shape, and a diameter of from 0.5μ to 2.0μ. Although not overlooking the possibility that their presence in the blood might have resulted from post-mortem contamination, he advanced a theory that they might be responsible for a kind of nitrogen "fixation," their presence in the blood thus serving to protect the whale from caisson sickness. Subsequently, however, Laurie (1935) stated that further research had failed to support his

hypothesis, and Scholander (1940) could find no X organisms in blood drawn from whales immediately after death. The latter author often saw bacteria in blood from older carcases, and he observed numerous cocci in blood from a sperm whale which had been dead for some time.

A smear from one of the examples of *Megaptera nodosa* studied at Tory Channel is completely free from bacteria. It shows no signs of external contamination, but the other three, in which the bodies resembling Laurie's X organisms are present, are all obviously contaminated. Dried globules of fatty material are present, and it is in the vicinity of these that the densest concentrations of bacteria occur. Smears of the blubber itself contain very great numbers of bacteria similar in every respect to those occurring in the blood. It is to be expected that the blood of harpooned whales will often come to contain immense numbers of bacteria, in addition to other contaminants, as a consequence of the organic destruction wrought by the explosion of the charge. Bacteria from the alimentary tract, from other internal sources, or from the surface of the body might well become widespread in the circulatory system during the time elapsing between the explosion of the charge and the failure of heart action. One spread through the bloodstream, these organisms would multiply rapidly enough to be present in great numbers by the time the whale became accessible to a biologist working on a factory ship or at a shore base. Even blood taken directly from vessels under sterile conditions would then, of course, be contaminated. This hypothesis affords an explanation for the presence of bacteria and a spirochaete in the blood preparations from the humpback whale. The single example of this species recorded as having a normal blood picture was, like some of the whales examined by Scholander, dealt with before bacteria introduced into the bloodstream had had time to multiply throughout the vessels.

Monocercomonoides AND *Chilomastix*.

During October, 1947, 137 sheep (*Ovis aries* L.) were examined at the Wellington City Corporation abattoirs. In the majority of cases, smears were made directly from the hearts of freshly slaughtered animals, but a meat inspector who was assisting me made a number of preparations from blood dripping from the necks of hung and gutted carcases. Several of these latter smears proved to contain numerous flagellates referable to the genera *Monocercomonoides* and *Chilomastix*. These protozoans commonly form part of the fauna of the lower intestine of various animals. Having gained access to the blood when the posterior end of the rectum was severed, they must have been carried down to the neck when the carcases were hung up. Intestinal protozoa are best prepared for study by wet fixation, followed by staining utilizing one of the "never-dried" techniques. As the material in question was intended for the study of haematozoa, the smears were air-dried, fixed in methyl alcohol, and stained with Giemsa. Consequently, the flagellates are so poorly fixed and stained that little more than their generic features can be made out. All the examples of *Monocercomonoides* are too badly hypertrophied for measurement, and nuclear detail cannot be distinguished. Four flagella originate in pairs from two blepharoplasts, which are situated in front of the nucleus and connected to each other by a rhizoplast. From one of the blepharoplasts, a fine axostyle runs back to the posterior end of the body. The *Chilomastix* has an ovoidal body, averaging 8μ by 6μ, and tapering sharply posteriorly to a slender caudal process some 5μ in length. The cytostome lies in the anterior two-fifths of the body, and a few examples seen contain ingested bacteria. Three subequal anterior flagella are present, the length of these being somewhat less than that of the body.

Apart from the presence in them of flagellates, the smears bear remarkably little evidence of contamination, considering their origin. This provides an excellent example of the dangers attendant upon describing material from preparations collected by others, without full knowledge of the circumstances of collection. Other investigators have recorded various intestinal flagellates as contaminants in blood. Martoglio (1917) went so far as to establish a new genus, *Haematrichomonas*, for trichomonads from this source. Wenyon (1926) and Cooper and Gulati (1928) have summarized the references dealing with trichomonads in blood smears. There are no grounds for accepting any of the cases recorded as other than examples of the adventitious invasion of the circulatory system by intestinal flagellates.

VEGETABLE CELLS RESEMBLING HAEMATOZOA (Text-figures 3 and 4).

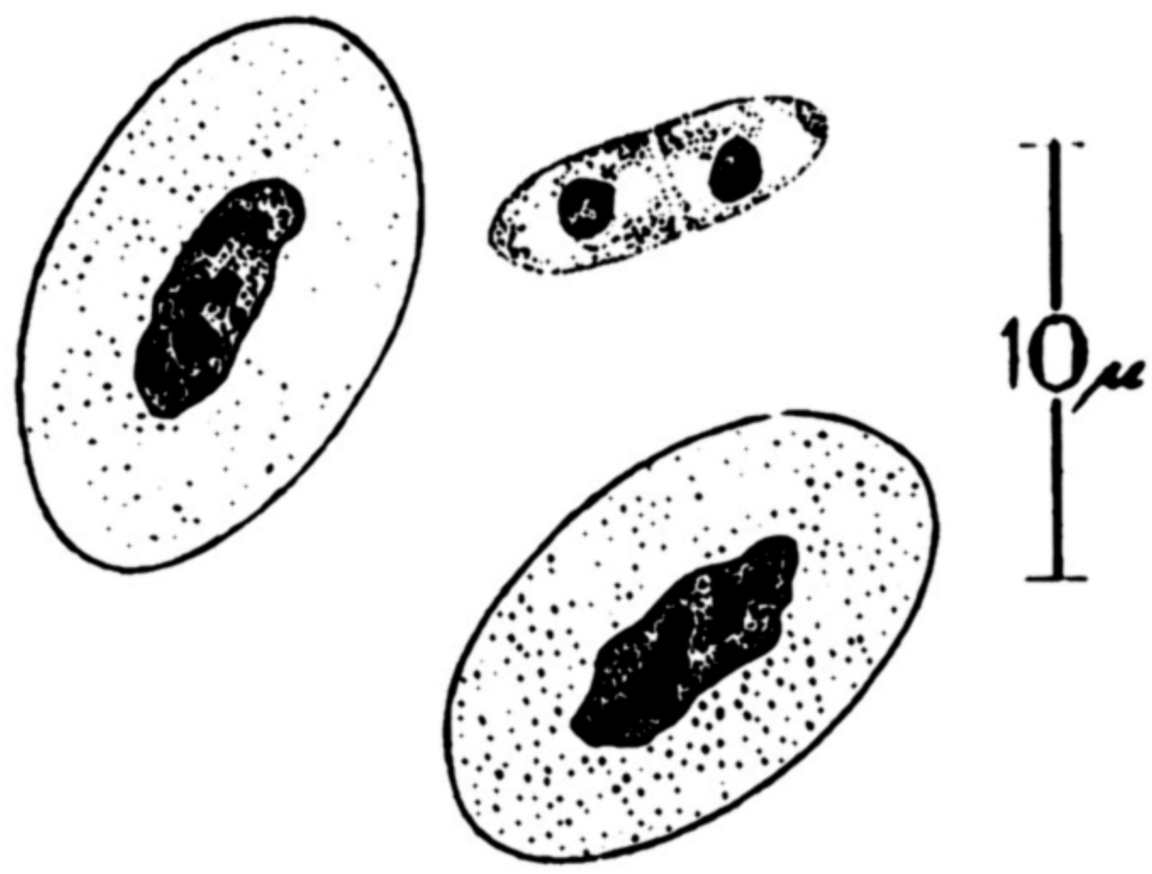

TEXT-FIGURE 3

Vegetable cell from a blood smear of *Cygnus atratus*. Two erythrocytes figured for size comparison.

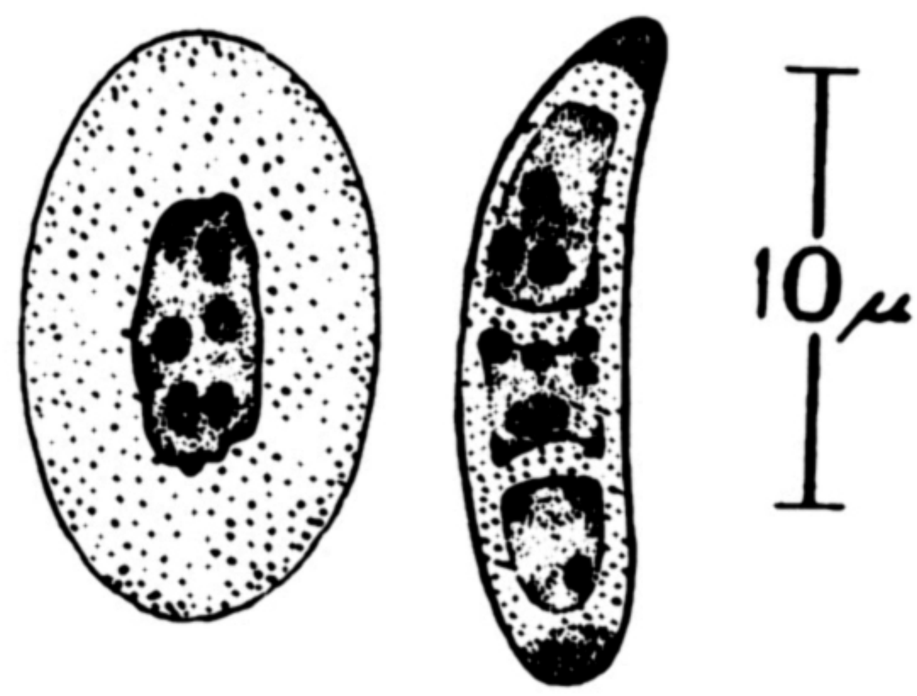

TEXT-FIGURE 4

Vegetable cell superficially resembling a spore of *Sarcocystis*, from a blood smear of *Porphyrio poliocephalus*. An erythrocyte is figured for size comparison.

A large number of blood smears were taken from game birds shot in the vicinity of Lake Wairarapa during May, 1947. Many of these were obtained by approaching sportsmen for permission to examine the birds they had shot. Most of the shooters were unwilling for a dissection to be carried out to allow blood to be obtained from the heart, so that smears usually had to be prepared from a superficial vessel or from shot wounds. Thus many of the preparations became contaminated with vegetable cells and bacteria. One dividing vegetable cell (Text-fig. 3), found in a smear from the Australian black swan *Cygnus atratus* (Latham), has (as seen in a Giemsa preparation) light blue cytoplasm and two red-staining nuclei. This cell bears a remarkably close resemblance to an artefact described by Bousfield (fig. reproduced by Wenyon, 1923) from a splenic smear from a case of kala-azar in the Sudan.

Text-fig. 4 illustrates another vegetable cell, probably a fungal spore, from a blood smear from a pukeko, *Porphyrio poliocephalus* (Vieillot). This cell (Giemsa preparation) is bounded by a red-staining capsular wall and has a deep red "polar cap" at each end. The cytoplasm has a maculated appearance, and is divided into three clearly demarcated blocks. It is stained deep blue, and contains a number of deep red granules. The organism resembles a spore of *Sarcocystis* in its shape (curved, one end being more pointed than the other), in its measurements (15.9μ by 4.0μ), and in having polar caps. Spores of *Sarcocystis*, however, are not

three-chambered. Careful focusing established that the organism in question had alighted on the slide following smearing, for it is in sharpest focus at a level above that of the plasma on which it rests.

LITERATURE CITED

COOPER, H., and A. N. GULATI, 1928: Occurrence of trichomonad flagellates in the blood stream of fowls. *Agr.Res.Inst.Pusa*, Bull. 173, 1–9.

LAURIE, A. H., 1933: Some aspects of respiration in blue and fin whales. *Discovery Repts.*, 7, 363–406.

———, 1935: Physiology of whales. *Nature*, 135 (3420), 823.

MARTOGLIO, F., 1917: Su di un nuova genere di parassiti del sangue. *Annali d'Igene*, 27, 561.

SCHOLANDER, P. F., 1940: Experimental investigations in the respiratory function in diving mammals and birds. *Hvalradets Skrifter*, 22, 1–131.

TYZZER, E. E., 1942: A comparative study of Grahamellae, Haemobartonellae, and Eperythrozoa in small mammals. *Proc.Amer.Phil.Soc.*, 85 (4), 359–98.

WEINMAN, D., 1944: Infectious anemias due to *Bartonella* and related red cell parasites. *Trans.Amer.Phil.Soc.*, n.s., 33 (3), 243–350.

WENYON, C. M., 1923: "Haemogregarines" in man, with notes on some other supposed parasites. *Trop.Dis.Bull.*, 20 (7), 527–50.

———, 1926: Protozoology. London, Baillière, Tindall and Cox. Vol. II, ix + 779–1563.